

## Polycaprolactone Tissue Scaffolds Based on Computed Tomography for Temporo-Mandibular Joint Reconstruction

S. Das, S.J. Hollister, Haseung Chung, C.M. Flanagan, M.H. Smith, S.E. Feinberg  
University of Michigan, Ann Arbor

**Statement of Purpose:** The objective of this study was to design, fabricate, implant and evaluate a prototype condylar ramus unit (CRU) scaffold for Temporo-Mandibular Joint (TMJ) reconstruction in a Yucatan minipig condylectomy model. The aims of study were to: (a) design a CRU scaffold based on computed-tomography (CT) data to fit the anatomy, allow function, and provide sufficient mechanical support during the condyle regeneration process. (b) fabricate scaffolds using polycaprolactone (PCL), a bioresorbable polymer, by selective laser sintering. (c) Implant the scaffolds packed with autologous bone marrow in minigs and evaluate the scaffolds for regeneration.

**Methods:** Computed-tomography data from mini-pigs was processed using image-based methods to design a CRU scaffold. The implant was created in several steps, including dilation of CT data to create a posterior ramus-fitting sleeve and erosion to create the articulating condyle surface. The image-based design was converted to .STL file format and manufactured via Selective Laser Sintering (Sinterstation 2000<sup>TM</sup>, 3D Systems, CA) from PCL powder (CAPA 6501, Solvay, UK). A unilateral condylar head osteotomy (from base of sigmoid notch posteriorly through the ramus) was performed in 5 minipigs. The CRU scaffold condylar head was packed with autologous bone marrow and the sleeve was aligned and fixed on the ramus using five 2.3mmD screws (KLS, FL). The animals were sacrificed at 1 and 3 month timepoints. The retrieved scaffolds were histologically evaluated and also digitally reconstructed by micro-computed tomography ( $\mu$ CT).

**Results / Discussion:** Post-surgery, all animals returned to normal masticatory function for the study duration. At sacrifice, there was no evidence of implant or fixation failure. Micro-computed tomography and histologic data illustrated bone growing within condylar head scaffold boundaries at both timepoints. Additionally, in some animals an extraneous bony cap (with cartilage present on some surfaces including adjacent to the disc) formed superior-anterior to the implant condyle boundary.

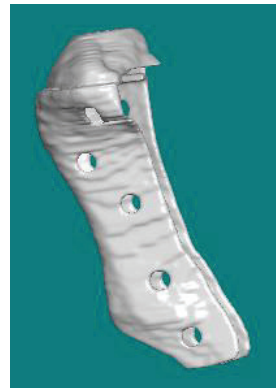**Conclusions:** This study illustrates the successful use of a CRU scaffold made using PCL, a bioresorbable polymer. The scaffold designed using computed-tomography data, closely matched the TMJ anatomy. It allowed normal masticatory function, provided mechanical support, and supported growth of bone and cartilage. Future investigations will include design refinements that will guide tissue development within the scaffold confines.

### References:

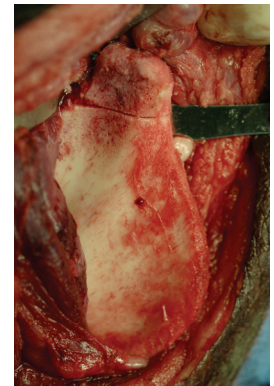
1. Hollister et al, Orthod Craniofacial Res 2005; 8:162–173.
2. Williams et al, Biomaterials 2005; 26:4817–4827.
3. Partee et al, ASME J. Manuf Sci Eng 2006.

### Acknowledgements:

NIH BRP DE13608, NIH R21 DE014736



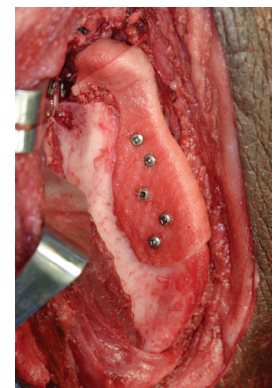
Scaffold design



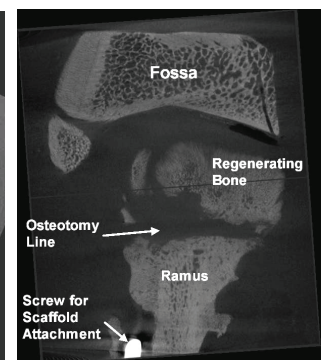
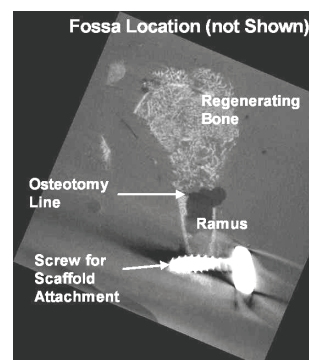
Minipig Condylectomy



Packed scaffold



Scaffold fixed onto ramus



Microcomputed tomography of retrieved scaffold showing bone regeneration