

Mid-Term Survivorship of a Press-Fit, Plasma-Sprayed, Tri-Spike Acetabular Component

Klaassen MA, Martinez-Villalobos M, Pietrzak WS, Mangio-Pariente G, Carranza-Guzman D.

OSMC, Elkhart, IN; Biomet Orthopedics, Inc., Warsaw, IN

Statement of Purpose: Although total hip arthroplasty procedures are quite successful, late aseptic loosening of the components secondary to osteolysis remains a concern. (1) This is often mediated by wear particle generation and a migration pathway to the periprosthetic tissue. In the case of an acetabular press-fit cup, the presence of screw holes and the nature of the porous bone-ingrowth coating can affect the migration pathway. Other factors such as the type of polyethylene from which the cup liner is fabricated, can influence wear particle generation. These principles suggest that a press-fit cup without screw holes that includes a porous coating with non-interconnecting pores, coupled with a wear-resistant polyethylene liner, should result in a low incidence of aseptic loosening. Our purpose was to clinically examine the survivorship of a press-fit, porous-coated (non-interconnected pores) tri-spike cup, without screw holes, when used with a wear-resistant polyethylene liner.

Methods: This was a retrospective study of 44 patients (45 hips), mean age 67 years (range: 34-88 years). All underwent total hip arthroplasty during 3/97 to 8/98, receiving the press-fit Ti6Al4V Tri-Spike™ cup (Biomet Orthopedics, Inc., Warsaw, IN). This component has a porous plasma sprayed Ti6Al4V coating (non-interconnected pores), and a threaded dome hole that can be sealed with a plug. The cup liner was fabricated from Arcom® (Biomet Orthopedics, Inc.) polyethylene and engaged with the cup by means of the Ringloc® (Biomet, Orthopedics, Inc.) mechanism. Arcom® polyethylene has been shown to possess excellent wear resistance. (2) Femoral components were press-fit or cemented. Last mean follow-up was 7.3 years (range: 4.0-9.0 years). At follow-up, radiographic assessment was performed. Cup inclination angle was measured and retroacetabular radiolucency lines per DeLee and Charnley (3) were identified, comparing values at the 2-month and final follow-up intervals (cup inclination angles were available at both time intervals only for 26 hips). A paired t-test was used to statistically compare cup inclination angles at both intervals. Kaplan-Meier survivorship curves were calculated using both cup revision and retroacetabular radiolucency as endpoints.

Results/Discussion: No Tri-Spike™ cups were removed or revised. Only one hip had evidence of two <1mm retroacetabular radiolucent lines (zones 1 and 2 of DeLee and Charnley) at 3 year follow-up. This patient presented with clinical symptoms and radiological signs of aseptic loosening of the cemented femoral component. During revision surgery, only the femoral component was revised as the cup was well fixed into the acetabulum. Follow-up at year 4 (from the date of primary surgery) showed no progression of the retroacetabular radiolucencies. Kaplan-Meier survivorship curves are shown in Figures 1

and 2, based on cup revision/removal and occurrence of radiolucency, respectively. Using cup revision/removal as an endpoint, projected survivorship was 100% at 9 years. Using development of radiolucency as an endpoint, survivorship was 97.8% at 9 years (95% confidence interval: 93.5-100%).

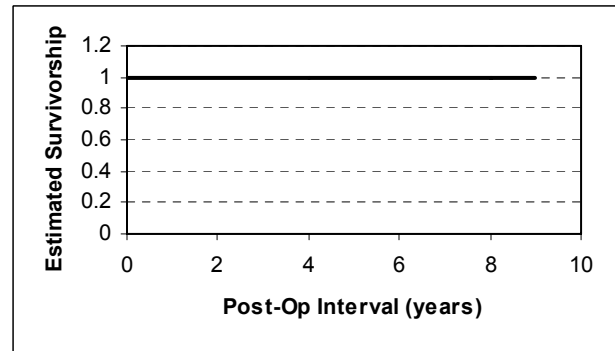


Fig. 1. Kaplan-Meier survivorship for removal/revision.

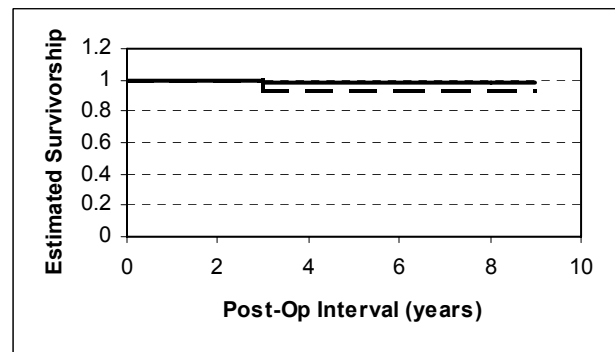


Fig. 2. Kaplan-Meier survivorship for radiolucency.

Two-month and final follow-up mean cup inclination angles (26 hips) were $48.5 \pm 9.7^\circ$ and $49.1 \pm 9.1^\circ$, respectively, and were not significantly different ($p=0.080$). This indicates that cup position was stable. According to Engh, et al. (4), survivorship rates with cup loosening as an endpoint, decline at the rate of about 0.5%/year for the first seven years and about 2%/year for years 7-15. As such, the survivorship of the Tri-Spike™ acetabular cup compares favorably with that of published values.

Conclusions:

The Tri-Spike™ cup exhibited excellent mid-term survivorship. While it is possible that the design features of the cup and liner contributed to these results, this remains speculative and must await further study. Ideally, future studies will include an estimate of polyethylene wear.

References:

1. Muller U. J Bone Joint Surg Am. 2003;85-B:31-36.
2. Head WC. 11th Annual Winter Symposium, Steamboat Springs, CO January 2001.
3. DeLee JG. Clin Orthop. 1976;121:20-32.
4. Engh CA. J Arthroplasty. 2004;19(Suppl 2):54-60.