

Hemorrhage Control Using an Internal Chitosan Hemostatic Dressing in Hepatic Injuries in Swine

Lisa D. Lucchesi, Hua Xie, Jeff Teach, Ping-Cheng Wu, Susie Shrimpton, Kathy Shultz, Genevieve Hillis, Rebecca Rowe, Allen Burke*, Jian Guo, Kenton W. Gregory
Oregon Medical Laser Center, Providence St. Vincent Medical Center, Portland OR
*CV Path, Gaithersburg, MD

Purpose: The goal of this study is to evaluate the use of an internal chitosan hemostatic dressing (ICHD) as a fast, convenient, and reliable technique to control hepatic vascular bleeding following a Grade III injury in a porcine model (1). External Grade chitosan hemostatic dressings have been shown to increase survival rates, reduce blood loss, and reduce resuscitation fluid requirements following severe liver injuries in swine (2). Our hypothesis is that the ICHD group will have less post-treatment blood loss and an increased survival rate at 24 hours.

Materials and Methods: The ICHD consisted of lyophilized Ultrapure chitosan sponges with and without Tepha® backing prepared by OMLC, Figure 1. The control was Kendall (Tyco Healthcare) regular sterile 4" X 4" surgical gauze.




Figure 1: Left: 2" X 2" ICHD. Right: SEM of ICHD with Tepha® (top) and chitosan lamellae structure below (407x).

The hepatic injury was made on heparinized domestic swine using a #11 surgical blade to create an "X" shaped injury, which leaves a wound with a 2 cm X 2 cm length of cross-line and a depth of 3 cm. The study was designed with two treatment groups. In the ICHD group, a non-Tepha® backed dressing was packed into the wound and the wound surface was sealed using an additional Tefha® backed dressing for covering. Two pieces of 4" x 4" Kendall gauze was then applied to the top of the ICHD cover dressing and manual pressure held for 3 minutes. In the control treatment group, an identical wound was created and repaired using 4" x 4" Kendall gauze as packing and cover dressing. If bleeding occurred, 2 repeat applications were given. If hemostasis was achieved at one hour the abdomen was closed and the animal was allowed to recover and observed for 24 hours. Initial hemorrhage rate, pre-treatment and post-treatment blood loss data were collected.

Results: Initial hemorrhage rate was 78±52 cc/min and 74±37 cc/min for the ICHD and gauze, respectively. The pre-treatment blood loss for ICHD and gauze were 109±54g and 73±18g, respectively. There were no significant differences in both the initial hemorrhage rate and pre-treatment blood loss. The post-treatment blood loss for chitosan and gauze were 99±155g and 2317±1731g, respectively ($p < 0.01$, Student's t-test). The survival rate after 24 hours was 100% (n=11) for the ICHD treated swine as compared to 33% (n=3) for the gauze treated swine. Histological results of the chitosan patch after 24 hours demonstrated minimal tissue reaction with relatively little hemorrhage or hematoma, indicating adequate hemostasis, Figure 2.

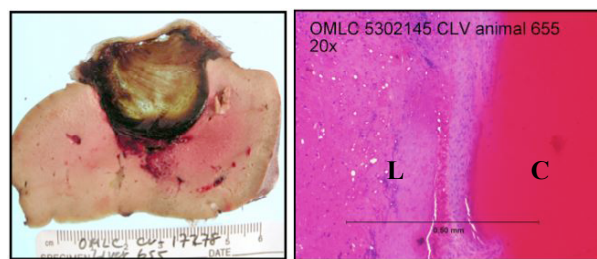


Figure 2: Left: Gross photograph of ICHD liver repair. Right: ICHD (C) and liver (L) interface (20x, hematoxylin-eosin stain)

Discussion/Conclusions: The efficacy of the ICHD to treat Grade III liver injuries was demonstrated in this sub-acute study. The histology shows that the ICHD conformed well and uniformly sealed the wound surface of the liver. The post-operative blood loss was significantly reduced and the 24-hour survival rate of the ICHD treatment was superior to the gauze control treatment. A chronic study using the same Grade III injury model is underway to determine the biocompatibility of the ICHD in the liver healing process.

References:

- (1) Moore E.E., et al: "Organ injury scaling : Spleen and Liver." J. Trauma 38, 323-324, 1995.
- (2) Pustateri A.E. et al. "Effect of a chitosan-based hemostatic dressing on blood loss and survival in a model of severe venous hemorrhage and hepatic injury in swine." J. Trauma. 2003; 54: 177-182.

Acknowledgements:

This project was sponsored by the Department of the Army, Grant No. DAMD 17-01-2-0030.