

# Causes of Intraocular Lens Opacification or Discoloration: Analyses of Explants

Liliana Werner, MD, PhD

John A. Moran Eye Center, University of Utah, and Berlin Eye Research Institute

**Statement of Purpose:** The aim of this ongoing study is to analyze and report causes of opacification and discoloration of intraocular lenses (IOLs) manufactured from different biomaterials and in different designs. This series relates to pseudophakic IOLs, used in cataract surgery.

**Methods:** The explanted lenses were sent to the John A. Moran Eye Center, or to the Berlin Eye Research Institute in the dry state, or immersed in solutions such as balanced salt solutions and fixatives. They underwent gross and light microscopic evaluations, at a minimum. Some specimens also underwent special histochemical staining (e.g., alizarin red, von Kossa), and/or were forwarded to other centers for more specialized analyses, such as scanning electron microscopy (SEM), energy dispersive x-ray spectroscopy (EDS), gas chromatography-mass spectrometry (GC-MS), among others.

**Results:** Our analyses revealed that different pathologic processes may lead to clinically significant opacification or discoloration of the optic component of IOLs manufactured from different biomaterials and in different designs. Factors such as patient's associated conditions, IOL manufacture, IOL storage, surgical techniques and adjuvants, among others, may be involved in different combinations. The complication may already be observed intraoperatively, or only postoperatively, from few hours after lens implantation to many years after surgery, depending on the processes involved. The types of processes identified included: formation of deposits/precipitates on the IOL surface or within the IOL substance, IOL opacification by excess influx of water in hydrophobic materials, direct discoloration of the IOL by capsular dyes or medications, IOL coating by substances such as ophthalmic ointment and silicone oil, and slowly progressive degradation of the lens biomaterial (**Figure 1**).

**Conclusions:** Different factors may be involved in a process of IOL opacification or discoloration. The process may involve IOLs manufactured from different biomaterials, and be observed intraoperatively, early postoperatively, or late postoperatively. With the increasing numbers of new IOLs in the market every year, constant vigilance is necessary.

## References:

-Dahle N, Werner L, Fry L, Mamalis N. Localized, central optic snowflake degeneration of a PMMA intraocular lens: Clinical report with pathological correlation. *Arch Ophthalmol* 2006; 124:1350-1353.

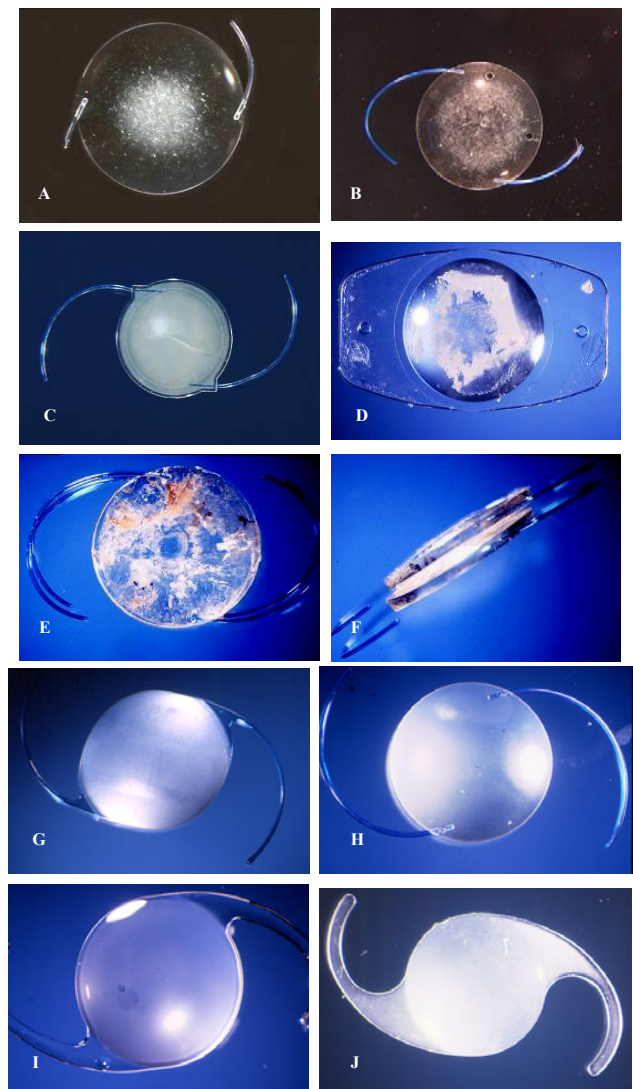
-Werner L, Dornelles F, Hilgert CR, et al. Early opacification of silicone intraocular lenses: Laboratory analyses of six explants. *J Cataract Refract Surg* 2006; 32:499-509.

-Foot L, Werner L, Gills JP, et al. Surface calcification of silicone plate intraocular lenses in patients with asteroid hyalosis. *Am J Ophthalmol* 2004; 137:979-987.

-Werner L, Apple DJ, Pandey SK, et al. Analysis of elements of interlenticular opacification. *Am J Ophthalmol* 2002; 133:320-326.

-Werner L, Hunter B, Stevens S, et al. Role of silicon contamination on calcification of hydrophilic acrylic intraocular lenses. *Am J Ophthalmol* 2006; 141:35-43.

-Werner L. Causes of intraocular lens opacification or discoloration. *J Cataract Refract Surg* 2007; 33:713-726 (Review).



**Figure 1:** Examples of IOLs explanted because of postoperative opacification. A and B: PMMA IOLs. C and D: Silicone IOLs. E and F: Hydrophobic acrylic IOLs. G-J: Hydrophilic acrylic IOLs.