

Bone Ingrowth in Revision Acetabular Components Retrieved Postmortem

Hall DJ, Urban RM, Dahlmeier EL, Laurent MP, Della Valle CJ, Galante JO, Jacobs JJ
Dept. of Orthopedic Surgery, Rush Medical College, Chicago, IL 60612

Purpose: There is a paucity of data on the actual nature of the bone-implant interface of revision acetabular components and on how treatment of substantial bone deficiencies with allograft and/or autograft bone might affect bone ingrowth. The purpose of this study was to quantify the presence of bone and soft tissues at the bone-implant interface of revision components retrieved post mortem, to compare this data with previous findings for primary components, and to examine the effects of autologous and allogenic bone graft on bone ingrowth into acetabular components in the revision environment.

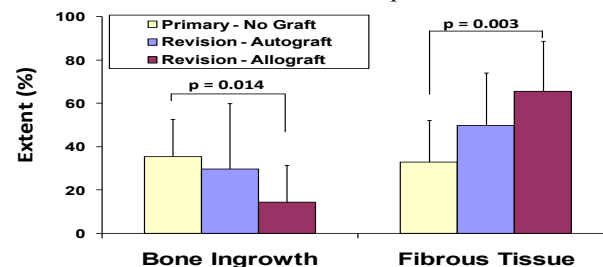
Methods: 17 revision cementless acetabular components (12 HG1, 5 HG2, Zimmer, Warsaw, IN) implanted with the use of 0 to 6 screws were retrieved postmortem from 9 males and 8 females after a mean of 10.5 (0.1-17.2) years. The reasons for revision were aseptic loosening of a cemented cup in 15 cases and two-stage revision for infection in 2. The mean age at revision was 67. Preoperatively, 4 acetabula had a Paprosky grade 2A defect, 8 acetabula a 2B, 1 a grade 2C, and 2 had a grade 3A acetabular defect. In 9 cases, the reconstruction was supplemented with freeze-dried particulate cancellous allograft bone alone; another 6 cases received the particulate allograft plus cancellous autograft bone and/or marrow; and 2 cases received only autograft bone. The mean Harris Hip Score at last followup was 81 (36 to 97).

Undecalcified, stained sections of the acetabular shell with adjacent bone and soft tissues were studied using light microscopy. The extent of bone and various soft tissues was estimated using a point-counting grid and expressed as the percentage of fields positive for each type of tissue. The area fraction of bone ingrowth was determined using computer analysis of back-scattered SEM images. The data for revision components were compared to a subset of data on primary HG acetabular components of similar duration (mean 10.6 yrs, range 1.8-18.1 yrs, $p=0.945$), previously reported [1]. Incorporation of bone graft and the relationship between the type of bone graft used and bone ingrowth into the component were assessed. The final radiographs were reviewed for radiolucencies and migration. Data were analyzed using Mann-Whitney tests and Spearman correlations.

Results: Interface tissues in revision acetabular components were complex, demonstrating bone ingrowth, both viable and necrotic bone graft, particle-induced granulomas, retained bone cement, areas of fibrosis, and remaining bone deficits. The histomorphological studies indicated that overall the area fraction of bone ingrowth into revision components was significantly less than observed in primary arthroplasties ($p=0.024$).

Acetabular revisions supplemented with allograft alone had significantly less bone ($p=0.014$) and more fibrous tissue ($p=0.003$) than primary reconstructions (Figure). Acetabular revisions supplemented with autograft bone tended to have a greater extent of bone ingrowth (29.7%) and less fibrous tissue (49.8%) compared to those in

which only allograft bone (14.2% and 65.6% respectively) had been employed. Of five revision components that had no bone ingrowth, 4 were associated with large discontinuities in the acetabular wall measuring 1 mm to 20 mm in greatest dimension. Particles of bone allograft without evidence of new bone formation and surrounded by fibrous tissue were present within unhealed acetabular defects and at the bone-implant interface.



There was good agreement between the clinical radiographic assessment of revision acetabular components and the histomorphological evaluation of bone ingrowth. Of the 9 components with less than 4 radiolucent zones, 8 had between 11% and 68.5% extent bone ingrowth. Of 7 components with 4 to 5 radiolucent zones, 4 had some bone ingrowth (0.3 to 7.0%) and 3 components lacked bone ingrowth.

Conclusions: Cementless acetabular revision remains a challenge in the setting of large bone defects. Intimate contact with viable bone and initial implant stability are essential conditions for achieving bone ingrowth into porous materials. Not surprisingly, the revision components in this study had significantly less bone ingrowth and more fibrous tissue than primary implants of similar design and duration. This was particularly so for cases with large, remaining discontinuities in the acetabular wall. The amount of bone ingrowth required for durable fixation of an acetabular cup is not known, but previous studies of primary implants have shown excellent clinical results with a relatively small amount of ingrowth, provided it covers a substantial portion of the interface [1]. Results of the present study suggest this is also valid for revision components. The goal of maximizing the initial amount of bone growth remains important, because over the long term, bone ingrowth can decrease due to particle-induced osteolysis or metabolic bone disease, potentially leading to failure of fixation.

The use of bone graft at the host bone-implant interface is one way of enhancing bone ingrowth in the revision environment where the quality of the bone bed may be poor and large bone voids are often present. The results of this study also suggest that particulate allograft alone may not be sufficient for enhancement of bone ingrowth in revision arthroplasty, and that osteogenic material or allograft supplemented with such a material may be more effective in promoting bone ingrowth.

References: [1] Urban RM, et al. SFB, 2009.

Acknowledgement: NIH AR39310 and Zimmer