

Enhancing Segmental Defect Regeneration through a Thrombopoietic Agent

Wessel, Alexander¹; Bethel, Monique¹; Bemendorfer, Thomas¹; Harris, Jonathan¹; Wilhite, Jonathan¹; Millikan, Patrick¹; Burr, David¹; Fuchs, Robyn^{1,2}; Cheng, Yinghua¹; Kacena, Melissa¹; Chu, Tien-Min³

1. Indiana School of Medicine, Indianapolis, IN, United States. 2. Indiana University School of Health and Rehabilitation Science, Indianapolis, IN. 3. Indiana School of Dentistry, Indianapolis, IN, United States

Statement of Purpose: To enhance bone regeneration over segmental defects, bone morphogenic protein-2 (BMP-2) is commonly used. However, recently concerns have been raised over an increased incidence of cancer associated with its use, along with known risks of radiculitis in spinal surgery, heterotopic bone formation, and osteolysis. The search for a novel and safe osteoinductive agent has led our group to the discovery of the unique bone healing characteristics of thrombopoietin (TPO), the main megakaryocyte growth factor. To test its effects on bone healing, we created critical-size segmental femoral defects in both mice and rats and bridged the defects with biodegradable scaffolds imbued with either saline, TPO, or BMP-2. Bone healing was analyzed using x-ray, histology and micro-computed tomography (μ CT).

Methods: Male C57BL/6 mice and Long Evans rats underwent a 4mm or 5mm surgical resection to create artificial segmental femoral defects, respectively. This resulted in critical-sized defects that would not heal without intervention in the lifetime of the animal. The defects were filled with a poly(propylene fumarate)/tricalcium phosphate scaffold imbued with TPO (1 μ g in mice and 10 μ g in rats), BMP-2 (4 μ g in mice and 10 μ g in rats), or saline as a control. All scaffolds were held in place by a 27G needle (mice) or a retrograde 1.6mm intramedullary Kirschner wire (rats). Serial radiographs were taken every week (mice) or every three weeks (rats). At 15 weeks all animals were sacrificed and the femora dissected out. Femora underwent μ CT to better elucidate bone healing in the different treatment groups. The femora were then processed and sectioned for histological assessment under light microscopy following McNeal's tetrachrome staining to determine the amount of callus formation and the thickness of the underlying diaphyseal cortex.

Results: On serial radiographs (Fig 1.), the time to obtain callus formation in BMP-2 treated was about 2 weeks for mice and 3 weeks for rats, which was earlier than TPO group at about 4 weeks for mice and 6 weeks for rats. However, BMP-2 and TPO both exhibited a bridged callus at sacrifice. Saline control scaffolds failed to form a bridged callus. On μ CT examination (Fig 2.), femora treated with TPO more closely resembled the native size and contour of the native femora in comparison to the BMP-2 group, indicating more advanced bone remodeling at the time of sacrifice. On histology (Fig 3.), the femora treated with TPO had thicker cortices than the BMP-2 group, and callus formation was not as robust. Further histologic studies confirmed a more organized bone healing process with the TPO group.

Discussion: In comparison to BMP-2, TPO resulted in sufficient callus formation and improved bone remodeling that was more analogous to the native femur. Based on

previous biomolecular studies, we hypothesize that thrombopoietic agents are advantageous over BMP-2 because TPO activates both osteoblasts and osteoclasts resulting in both bone formation and remodeling, while BMP-2 activates only osteoblasts. Given that TPO appears to have a more benign side-effect profile in addition to its apparent superior ability to induce organized bone via remodeling, TPO could prove to be the next osteoinductive agent to effectively address problematic bone healing.

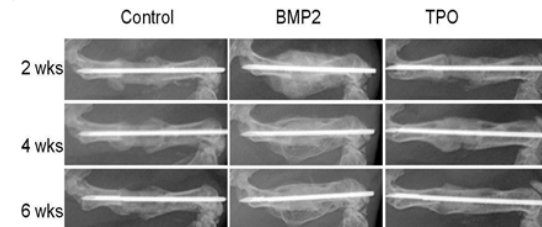


Fig 1. X-ray of mouse femurs 2, 4, and 6 weeks post-surgery with control (untreated), BMP-2, or TPO treated scaffolds.

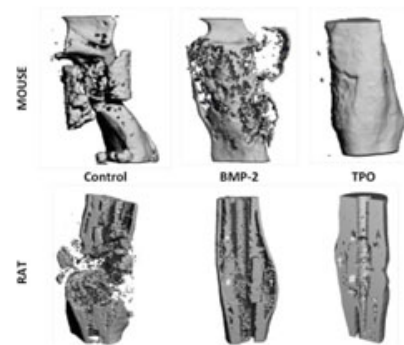


Fig 2. μ CT evaluation of mouse and rat mid-shaft femoral defects 15 weeks post-surgery, with control (untreated), BMP-2, or TPO.

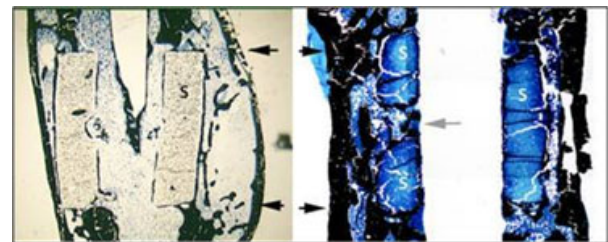


Fig 3. Representative micrographs of BMP-2 (left) and TPO (right) treated scaffold implanted in a rat femur for 15 weeks and evaluated under light microscopy. The scaffold is marked by "S". The dark arrows indicated the extent of the segmental defect created in the rat femur.