

Effect of novel putty-like resorbable calcium alkali orthophosphate bone substitute cements designed for restoring contours in craniofacial surgery on bone formation and osteoblastic phenotype expression *in vivo*

C Knabe, G Berger**, R Gildenhaar**, F. Dombrowski, K. Reiter, A. Houshmand, M Stiller

Department of Experimental and Orofacial Medicine, Philipps University Marburg, Marburg, Germany, **Laboratory for Biomaterials, Federal Institute for Materials Research and Testing, Berlin, Germany

Introduction: Although autogenous bone grafts are currently the standard of care for bone reconstruction, bone substitute materials are extensively studied in order to avoid harvesting autogenous bone. To fill bone defects, calcium phosphates are mainly applied as granules. For restoring outer contours in craniofacial surgery, however, putty-like mouldable bone substitutes with improved surgical handling properties are needed, which can be molded into the desired shape intraoperatively, then subsequently set in situ and also maintain the augmented bone volume over time. Over the past decade various bioactive calcium phosphate cements have been developed. In most cases hydroxyapatite is formed during setting, which limits their biodegradability. More recent developments include cements, which form calcium alkali phosphates during setting, which have been shown to have a stimulatory effect on osteogenesis *in vitro*,¹ and *in vivo*.² These cements are designed for higher biodegradability. This study evaluates the effect of four novel putty-like calcium alkali phosphate-based bone substitute cements on bone regeneration and expression of osteogenic markers after implantation in contour defects in the sheep mandible. This was in addition to examining the biodegradability.

Materials and Methods: Test materials were four resorbable mouldable putty-like calcium alkali phosphate-based bone substitute cements, which form the crystalline phases outlined in Table 1 and also have a small amorphous portion in addition to being supplemented with porcine gelatin. These four cements were compared to a tricalcium phosphate (TCP) putty material.

Table 1: main crystalline phases and amorphous portions of bone grafting cements examined

Cement	Main crystalline phase	Amorphous portion
GB14-Z	Ca ₂ KNa(PO ₄) ₂	magnesium potassium phosphate
GB9-Z	Ca ₂ KNa(PO ₄) ₂	silica phosphate
401545-Z	Ca ₁₀ [K/Na](PO ₄) ₇	SiO ₂
401545(70)-Z	Ca ₁₀ [K/Na](PO ₄) ₇ Ca ₂ KNa(PO ₄) ₂	SiO ₂

These cements were implanted in the sheep mandible and used to reconstruct the outer contour of the mandible in critical size-contour defects in the lower rim of the mandible. Empty defects served as control. Animals were sacrificed at 1, 4, 12, 24, and 48 weeks. At implant retrieval the tissue samples were fixed in an alcohol based fixative as described previously.³ Subsequently, the specimens were embedded in a resin, which facilitated performing immunohistochemical analysis on hard tissue sections.³ Sawed sections were then deacrylized and immunohistochemical staining was performed using primary antibodies specific to collagen type I (Col I), alkaline phosphatase (ALP), osteocalcin (OC), and bone sialoprotein (BSP), in combination with the DAKO EnVision+™ System.³ Semi-quantitative analysis of the

sections was performed. A scoring system quantified the amount of staining observed. A score of (+++), (++) and (+) corresponded to strong, moderate or mild, a score of (0) correlated with no staining. Also histomorphometrical evaluation of the sections was performed. To this end, the bone-area-fraction, the cement-area-fraction in the defects and the bone-cement-contact were measured using a light microscope and digital camera (Colourview III) and SIS Analysis software (Olympus, Germany).

Results: The GB9-Z and GB14-Z cements displayed excellent surgical handling properties and facilitated restoring the outer contour of the mandible in the critical size-defects as well as maintaining the augmented bone volume without any resorption over the 48 week observation period (Fig. 1), which was not the case for the TCP putty, while with the 401545-Z and 401545(70)-Z cements shrinkage during setting and implant loosening or loss occurred in 50% of the cases. GB9-Z and GB14-Z induced woven bone formation at their surface as early as 1 week after implantation and stimulated bone formation at their surface inducing moderate to strong osteogenic marker expression of Col I, ALP, OC and BSP in osteoblasts, osteocytes and the bone matrix of the surrounding bone tissue at the various time points studied. They furthermore displayed excellent bone-bonding behavior, which was significantly higher than that of 401545-Z and 401545(70)-Z, and were gradually replaced by newly formed bone. In the empty control defects considerably lower bone formation was noted (Fig. 1) without adequate reconstruction of the outer contour of the mandible.

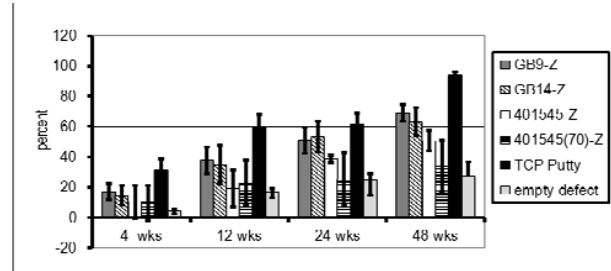


Figure 1. Bone area fraction in the grafted defect area. Thus, GB9-Z and GB14-Z facilitated excellent bone regeneration of contour defects in the sheep mandible. **Conclusion:** The putty-like calcium alkali phosphate-based bone substitute cements GB9-Z and GB14-Z are promising bone grafting materials for reconstructing contour defects in craniofacial surgery.

References:

1. C. Knabe, A. Houshmand et al., JBMR A, 2008,85,856-68.
2. C. Knabe, M. Stiller and P. Ducheyne In: Comprehensive Biomaterials, Vol. 6, Chapter 6.620, p. 305-324.
3. C. Knabe, B. Kraska et al., Biotech Histochem., 2006,81,31-9.

Acknowledgements: This work was funded by the European Union (EFRE-ProFIT grant # 10141914) and German Research Foundation (DFG KN377/8-1).