

PNDJ Delivering Gentamicin Controls Orthopaedic Infection in a Rabbit Model

Ryan McLemore¹, Derek Overstreet³, Alex McLaren¹, Brent Vernon²

Banner Good Samaritan Medical Center¹, Arizona State University², Sonoran Biosciences, Inc.³

Statement of Purpose: Carl Nelson and colleagues developed a standardized osteomyelitis model in the late 1990's. This model was employed by Nelson, et al, to evaluate a poly-anhydride based bead delivery system, "Biodel" © in 1997. Mikos, et al, employed this model to evaluate the efficacy of PLGA microspheres delivering tobramycin in 2004.

Nelson showed a cure rate of 4/16 animals (25%) with debridement +IM gentamicin sulfate, and 15/16 (93%) with Biodel beads at 20 wt% gentamicin sulfate[1]. Mikos showed a 25% (2/8) cure rate in the debridement alone group, and a cure rate of 37.5% (3/8) with PLGA micropsheres alone[2]. An additional parenteral 25 mg/kg of cefazolin was delivered IV 2x per day post-operatively to selected groups in the Mikos study, increasing the success in controlling the infection to 75% (6/8) when combined with the PLGA microspheres or 5/8 (63%) when combined with the ortho-set®. Mikos concluded that only the PLGA+tobramycin+iv cefazolin group was statistically different from the debridement alone, with a 25% vs 75% cure rate. In this study, we report on the effectiveness of our novel hydrogel, loaded with gentamicin, at controlling infection/osteomyelitis in a modified Nelson model in rabbits.

Methods: Two different batches of PNDJ copolymer (PNDJ15- 1.5 % Jeffamine, PNDJ22 -2.2 % Jeffamine) were synthesized by free radical polymerization. Hydrogel was mixed at 30 wt% in PBS with 50 mg/mL gentamicin sulfate. 16 white New Zealand female rabbits were divided into two groups, 8 to receive debridement only, and 8 to receive debridement plus gel with gentamicin. A 2cm long incision was made along the radius on the right fore-limb of each animal, separating muscles along fascial planes to reach the animal's radius. The periosteum was stripped from the radius using a scalpel and dissector. An approximate 1.25 inch length of the radius was removed using a small-toothed saw blade. An 0.045" k-wire was placed inside the length of the bone, and a micropipette was used to introduce 50 uL of a 10⁸ CFU/mL of *Stapylococcus aureus* in TSB solution. The microbe employed in this study is UAMS-1 (ATCC# 49230). Tissues were closed in layers with 3-0 prolene (Ethicon, Somerville, NJ). Buprenorphine was administered for pain management. All animals were survived 3 weeks post-surgically prior to debridement. Debridements were completed by a trained orthopaedic surgeon with experience in infection management. The surgeon was blinded during the debridement as to the treatment that the specimen was to receive, and animals were completed in random order.

Volume of the debrided space ranged from 300-800 uL, for a total dose per animal of ~9.9-26.4 mg of active gentamicin. Animals were allowed to survive for 4 weeks post debridement.

Cultures were routinely taken for all subjects at two time points: post debridement, and post treatment. Post

debridement, the k-wire, surrounding tissue, and any pus were carefully collected on a sterile swab supplied by the laboratory. Care was taken in the approach and handling of the tissue by the operating surgeon to avoid any contamination of the site prior to or after culture. Immediately post euthanasia, samples of the k-wire, suture and surrounding tissue were similarly collected in a sterile environment to avoid contamination. All samples were sent to IDEXX reference laboratory for independent verification of culture status. Any reported culture negatives were maintained for 21 days to ensure the absence of small colony variants before they were termed "negative" cultures. Infection rate was compared using the Fisher Exact Test.

Results: 16/16 animals had active infections as confirmed by culture after inoculation. Two of the subjects formed draining sinuses between the infection and the debridement procedure. Abscesses produced by the procedure were large and originated from involucrum formed around the retained radius fragment (Figure 1). Post debridement, 0/8 (0%) of animals who received debridement alone and had a replaced k-wire were cured, with culture results ranging from 2+ to 4+ for *Stapylococcus aureus*. 8/8 (100%) animals which received hydrogel were culture negative after 21 day negative culture retention. Gentamicin delivered by the hydrogel reliably prevented re-infection after debridement (p<0.001). Tissues which had received hydrogel showed apposition onto the k-wire remaining in the wound, whereas tissues that did not receive hydrogel had loose k-wires present, and several had large regions of pus present 4 weeks after surgery.

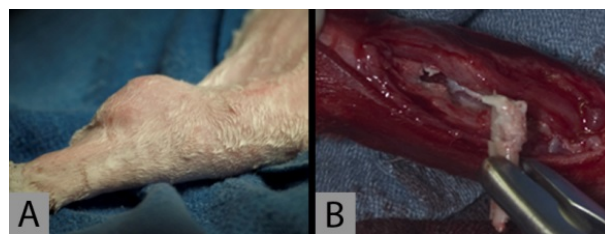


Figure 1: Infected Subject at Time of Surgery.

A) Large abscess formed subcutaneously in the tissues of the rabbit fore-limb. B) Involucrum and k-wire with tissues mid-debridement inferior to the abscess.

Conclusions: PNDJ gel with gentamicin reliably controlled infection in this animal model.

References:

- [1] Nelson CL, Hickmon SG, Skinner RA. Treatment of experimental osteomyelitis by surgical debridement and the implantation of bioerodable, polyanhydride-gentamicin beads. *J Orthop Res* 1997;15:249-55.
- [2] Ambrose CG, Gogola GR, Clyburn TA, Raymond AK, Peng AS, Mikos AG. Antibiotic microspheres: preliminary testing for potential treatment of osteomyelitis. *Clin Orthop* 2003:279-85.